

Investigation of symmetrical alopecia in dogs

Ross Bond

Introduction

Abnormalities of the hair coat are usually recognized by dog owners early in the course of a disease. Alopecia – absence of hair in an area where it is normally present – or hypotrichosis – partial hair loss – may present no risk to the patient and may be nothing more than a cosmetic problem, albeit one which may cause the owner considerable distress. Alternatively, it may be a manifestation of an internal disease with potentially serious consequences. A methodical approach and accurate diagnosis are prerequisites for successful management of these cases. The purpose of this chapter is to present an overview of the biology of hair growth and the mechanisms by which alopecia may develop, and to suggest an approach to the diagnosis of symmetrical alopecia in dogs, with emphasis on cutaneous endocrine disorders and their ‘impersonators’.

Anatomy and physiology

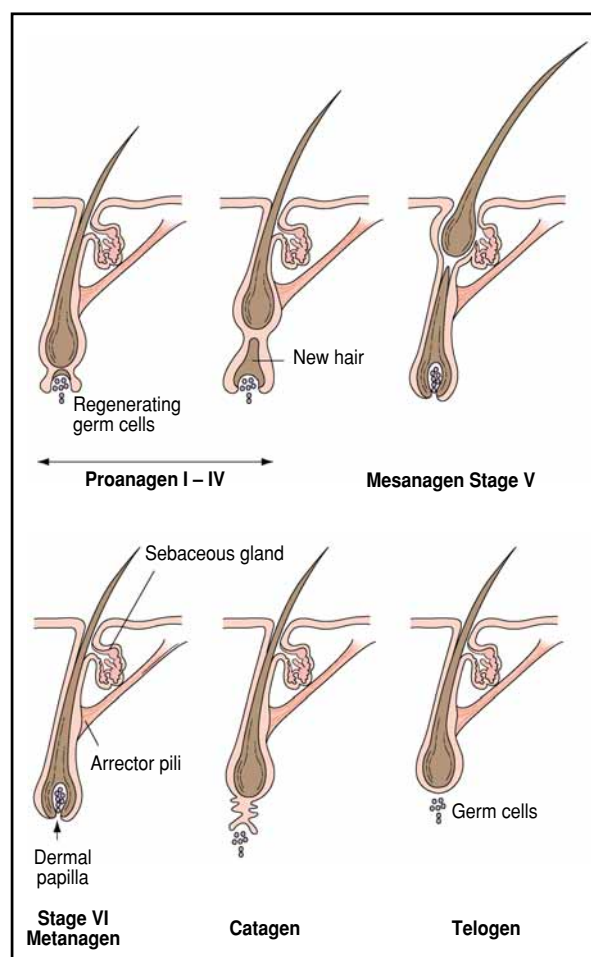
Dogs generally possess a dense hair coat that covers the entire skin surface, with the exception of the nasal planum, footpads, lips, teats and anus. The length, thickness, density and colour vary between individuals and especially between breeds. Dogs exhibit compound hair follicle grouping whereby a primary hair and 2–15 secondary hairs emerge through the same pore. There are 100–600 hair follicle ostia per square centimetre (Kristensen, 1975). Hair has important thermo-regulatory, protective and sensory functions.

The hair growth cycle

A cyclical pattern of hair shedding, followed by new growth and replacement has evolved.

- The growing or *anagen* phase is characterized by the production of a hair shaft. Stem cells located in the hair matrix (Figure 8.1) give rise to a population of epidermal cells that differentiate and keratinize, forming the hair shaft and inner root sheath. Anagen usually accounts for 80–90% of the duration of the hair growth cycle.
- The cessation of active hair growth signals the onset of *catagen*, a short transitional phase during which the inferior section of the hair follicle undergoes regression.

- The *telogen* or resting phase is characterized by a period of apparent inactivity during which the fully grown hair remains anchored in the follicle by an expanded and keratinized base known as a ‘club’. The hair shaft is normally retained in the follicle during catagen or telogen unless removed by vigorous grooming.



8.1

The hair growth cycle. Anagen, the active growth phase, is divided into 6 stages, Proanagen stages I – IV, Mesanagen stage V and Metanagen stage VI. During these stages, the hair follicle undergoes differentiation, rapid growth and hair elongation. Telogen represents the resting phase of the hair follicle and catagen is the transitional period between the growth and resting periods. (© Anita Patel; first published in *BSAVA Manual of Small Animal Dermatology*, 2nd edition.)

- Shedding of the hair only occurs after the next anagen phase has begun and a new hair shaft has entered the follicular canal.

In the dog, the hair growth cycle in each body region is asynchronous and the hair coat is replaced in a mosaic pattern.

Regulation

The hair growth cycle reflects the intrinsic rhythmic activity of the follicle, which results largely from local regulatory processes that are poorly understood. Dermal papilla cells (see Figure 8.1) are a permanent and stable population of specialized fibroblasts that interact with the follicular epidermis during embryonic development. In addition throughout adult life, they are thought to provide specific factors that stimulate both epidermal proliferation and follicular morphogenesis (Jahoda and Oliver, 1990).

Systemic factors are also important and several hormonal systems influence follicular activity. Hormones probably facilitate seasonal changes in follicular activity in response to environmental factors, such as photoperiod and ambient temperature (Ebling *et al.*, 1991). Gonadal, thyroidal, adrenocortical, pituitary and pineal hormones have been shown to influence the hair growth cycle in many species. For example, thyroxine (T4) accelerates the rate of hair growth and reduces the duration of telogen, whereas corticosteroids generally inhibit follicular activity (Ebling *et al.*, 1991).

Pathophysiology

Dunstan (1995) described an approach to diseases of hair follicles based on pathophysiological processes that provides a useful framework for consideration of the possible causes of alopecia. Diseases characterized by alopecia can be divided into scarring (or potentially scarring) and non-scarring disorders.

In *scarring* alopecia, there is destruction or distortion of the follicle, usually as a consequence of an inflammatory process, which means that hair regrowth is not possible. A common example would be deep pyoderma secondary to demodicosis.

By contrast, *non-scarring* alopecias generally result from structural or growth cycle abnormalities of the follicle without inflammation, and can be classified into four subtypes (Figure 8.2). Of these, atrophic diseases

associated with endocrinopathies are the most common cause of symmetrical alopecia in the dog. Follicular dysplasias, diseases characterized by incomplete or abnormally formed hair follicles and hair shafts, are less common but may clinically closely resemble an endocrinopathy. Some authors use the term ‘follicular dystrophy’ to describe these diseases (Gross *et al.*, 1992; Yager and Wilcock, 1994; Dunstan, 1995), which implies a disorder of structure and function caused by abnormal nutrition of the tissues.

Diagnostic approach

Alopecia may be a feature of myriad skin diseases, including:

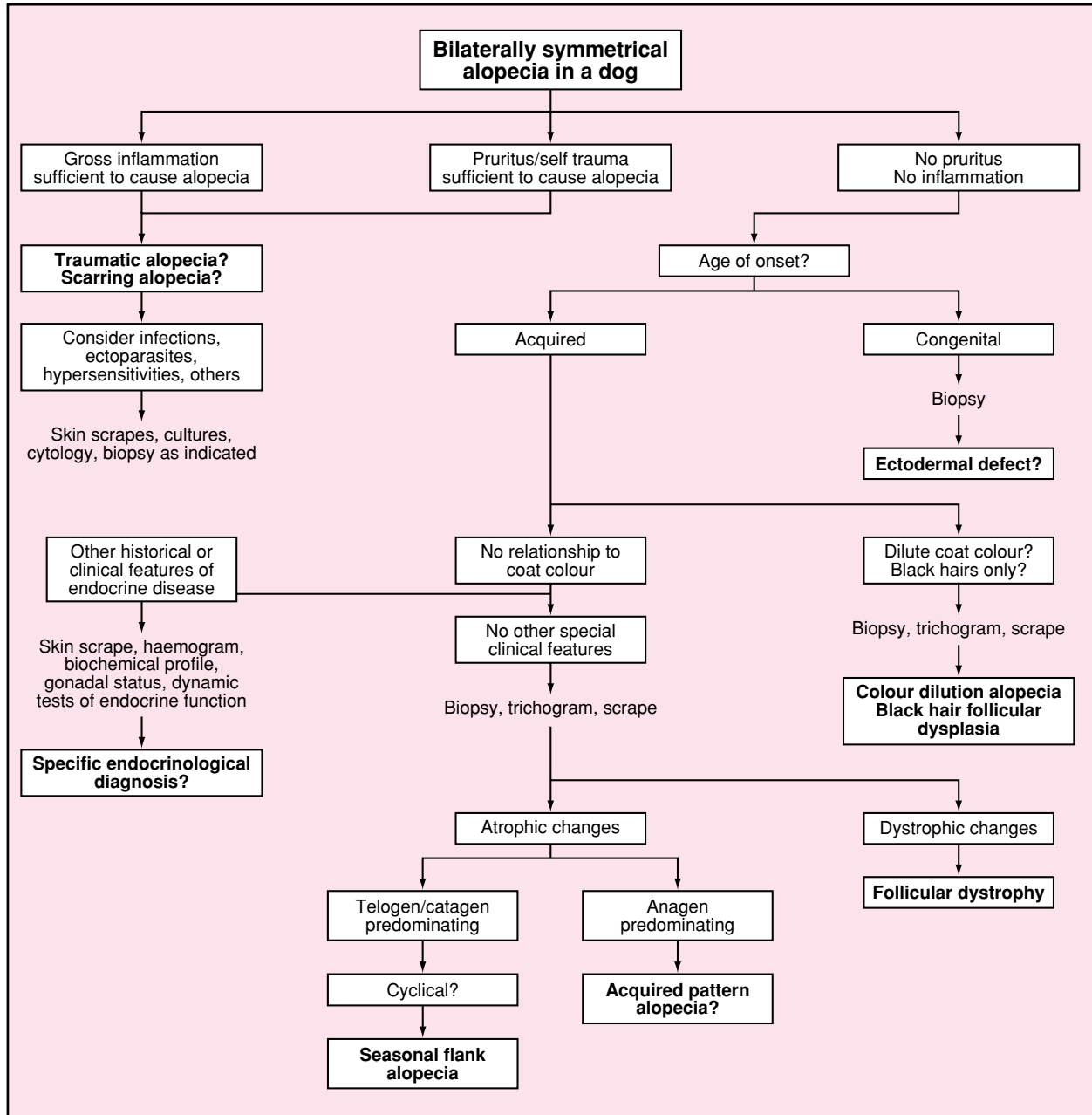
- Parasitic
- Allergic
- Endocrine
- Neoplastic conditions.

The list of differential diagnoses for dogs with symmetrical alopecia accompanied by marked pruritus and cutaneous inflammation is often lengthy, and a detailed discussion of the approach to this presentation is beyond the scope of this chapter. (For further information see Chapter 12 of the *BSAVA Manual of Small Animal Dermatology, 2nd edition*).

However, symmetrical alopecia without historical or clinical evidence of cutaneous inflammation is a relatively common presentation, and the presence of symmetrical skin lesions usually implies a systemically mediated disease. Acquired, bilaterally symmetrical, non-pruritic alopecia with easily epilated hairs and variable disturbances of skin and hair pigmentation is the classical presentation of atrophic hair follicle diseases associated with hormonal disorders. However, it is important to consider a number of ‘endocrine impersonators’, such as colour dilution alopecia and follicular dysplasias, when faced with this presentation. The diagnostic approach to symmetrical alopecia is initially based upon a consideration of the historical and clinical features. Further tests, which are usually required to establish a definitive diagnosis in such cases, are selected based on the historical and clinical findings (Figures 8.3 and 8.4).

Sub-types	Mechanism	Examples
Atrophic alopecias	Abnormal hair growth cycle leading to a shortened anagen – prolonged telogen phase (follicles are ‘asleep’)	Hypothyroidism, hyperadrenocorticism
Follicular dysplasias	Disorder of morphogens or structural proteins causing malformation of shaft or follicle such that hair growth is impossible	Congenital alopecia in Chinese crested dogs
Matrix cell/melanocyte abnormalities	Abnormal dispersal of melanosomes and/or disruption of matrix cells	Colour dilution alopecia, black hair follicular dysplasia
Traumatic alopecias	Hair removed in pruritic or psychogenic disease	Alopecia in allergic skin diseases

8.2 Types of non-scarring alopecia in the dog according to Dunstan (1995).



8.3 Suggested approach to the diagnosis of symmetrical alopecia in the dog. A case example is shown in Figure 8.4.

A 6-year-old neutered female black Cocker Spaniel was presented in August with a 4-month history of progressive non-pruritic symmetrical alopecia of the flanks. She was in good health otherwise.

The physical examination showed only alopecia without inflammation. The remaining hairs could be easily epilated in the affected areas. There were no other special features indicative of endocrine or systemic disease but a previous biopsy taken by another veterinary surgeon showed atrophic changes with telogen hairs predominating. This was interpreted by the pathologist as being consistent with an endocrine disease; dysplastic changes were not observed. There was no response to thyroid supplementation over one month. This treatment was stopped by the owner and a further opinion was sought.

History and clinical examinations confirmed no pruritus or inflammation. The age of onset excluded a congenital disorder. The dog was black all over, and a relationship to coat colour could not be determined. Parasites were not found on skin scrapings. Haemogram and biochemical profiles were normal. Thyroid stimulation tests and low-dose dexamethasone suppression tests were normal. While awaiting the results of the laboratory tests hair regrowth was evident, and complete regrowth was observed within 2 months.

These findings are most consistent with seasonal flank alopecia. In this case, alopecia recurred during the next spring and the hairs regrew again in the autumn, confirming the diagnosis. No treatment was given.

8.4 Case example: Symmetrical alopecia.

Chapter 8 Investigation of symmetrical alopecia in dogs

History

A general medical and dermatological history is required in all cases of skin disease. However, there are a number of points of particular relevance in cases of symmetrical alopecia.

Breed

Breed predilections (Figures 8.5 and 8.6) have been reported for many of the acquired endocrine diseases and are of particular importance in follicular dysplasias,

which have been recognized in Curly Coated Retrievers, Irish Water Spaniels, Portuguese Water Dogs, Siberian Huskies, Dobermann Pinscher and other breeds (Miller, 1990b; Gross *et al.*, 1992; Miller and Scott, 1995; Scott *et al.*, 2001a). Acquired pattern alopecia is most often seen in dachshunds (Figure 8.6).

Age at onset

The age of the dog at the onset of alopecia can be helpful. For example, congenital ectodermal defects

Disease	Underlying pathology	Breed predilection	Age at onset	Clinical signs (other than skin)	Special dermatological features
Hypothyroidism	Lymphocytic thyroiditis or idiopathic atrophy	Various, large breeds	2–10 years	Lethargy/exercise intolerance, weight gain, bradycardia, corneal lipid deposits	Cool, puffy, thickened skin (uncommon)
Hyperadrenocorticism (spontaneous)	Pituitary or adrenal neoplasia	Various, poodles, dachshunds, terriers	6–12 years	Abdominal enlargement, hepatomegaly, muscle wasting, testicular atrophy	Calcinosis cutis, thin skin, prominent superficial vessels
Alopecia X	Abnormal adrenocortical steroidogenesis. Mild hyperadrenocorticism?	Pomeranians, Keeshund, Miniature Poodle, Chow Chow, Samoyed, Alaskan Malamute	1–5 years	None	Hair regrowth at sites of biopsy or other trauma to the skin
Functional testicular tumour (male)	Hormone (oestrogen) production from testicular neoplasia	Not reported	Adult	Testicular mass, retained testes, prostatomegaly, attractiveness to male dogs, gynaecomastia, pendulous prepuce	None
Hyperoestrogenism (female)	Ovarian 'cysts' or functional neoplasia	Not reported	Adult	Enlarged nipples and vulva, irregular or prolonged oestrus, or prior oestrogen therapy?	None

8.5 Canine atrophic hair follicle diseases associated with endocrinopathies that commonly present as symmetrical alopecia. (Intended only as a guide. In some cases, the listed features may be absent).

Disease	Underlying pathology	Breed predilection	Age of onset	Clinical signs (other than skin)	Main diagnostic features
Telogen effluvium	Synchronous cessation of anagen, followed by shedding and regrowth	Not reported	Variable	Often nil, previous systemic disease or physiological stress	Rapid spontaneous resolution. Stressful event 1–3 months previously
Seasonal flank alopecia	Unknown. Related to photoperiod? Possibly mediated via pineal gland and melatonin	Dobermann Pinscher, Boxer, Airedale Terrier, Schnauzer	1–12 years (usually between 2 and 6 years)	None	Cyclical or seasonal course. Exclude other diseases
Oestrogen-responsive dermatosis	Unknown	Not reported	Adult	Infantile vulva? Urinary incontinence?	Exclude other diseases. Response to therapy (care)
Testosterone-responsive dermatosis	Unknown	Not reported	Adult	None	Exclude other diseases. Response to therapy (care)
Acquired pattern alopecia (pattern baldness)	Unknown	Manchester Terrier, dachshunds, Boston Terrier, Whippet	6–12 months	None	Histopathology: miniaturization of hair follicles

8.6 Atrophic hair follicle diseases of unknown or non-hormonal aetiology that may present as symmetrical alopecia. (Intended only as a guide. In some cases, the listed features may be absent).

causing alopecia from birth are occasionally encountered (Ihrke *et al*, 1993; Hoskins, 2001). Symmetrical, gross non-inflammatory alopecia acquired during the first year of life is suggestive of:

- Some follicular dysplasias
- Matrix cell/melanocyte abnormalities
- Congenital endocrine diseases, e.g. congenital hypothyroidism or pituitary dwarfism.

The most common acquired endocrine diseases, hypothyroidism and hyperadrenocorticism, are usually seen in middle-aged or elderly dogs.

Pruritus

A history of moderate or severe pruritus in a dog with symmetrical alopecia may indicate a traumatic aetiology or a scarring (inflammatory) disease. However, dogs with basic non-inflammatory diseases, such as endocrinopathies, may also be pruritic if the disease is complicated by a secondary microbial infection, the most common being staphylococcal pyoderma. If the distribution and severity of the pyoderma lesions do not correlate with the degree of alopecia, then the clinician should suspect an atrophic or dysplastic follicular disease underlying the skin infection. Re-evaluation after antimicrobial therapy may be helpful in such cases.

Signs of internal disease

In endocrine diseases such as hypothyroidism and hyperadrenocorticism, there may be historical features indicating abnormalities of other organ systems. For example, the owners of dogs with hyperadrenocorticism often report polyuria, polydipsia and polyphagia. In hypothyroidism, the owner may describe signs which reflect the slowing of cellular metabolism, such as lethargy and weight gain.

Recent stressful events

Telogen effluvium (telogen defluxion) is a transient disorder of excessive hair shedding resulting from a synchronous cessation of anagen, and usually follows pregnancy, lactation, severe illness or a similar stressful event that has occurred in the 1–3 months previously.

Seasonal or cyclical episodes

Seasonal or cyclical episodes of non-inflammatory symmetrical truncal alopecia followed by spontaneous hair regrowth are typical of seasonal flank alopecia (Miller and Dunstan, 1993; Curtis, 1995), and also occasionally occurs in follicular dysplasias, such as that seen in the Portuguese Water Dog (Miller and Scott, 1995).

Reproductive history

Male dogs with oestrogen-producing testicular tumours may have a history of signs suggesting feminization (attractiveness to male dogs, gynaecomastia, pendulous prepuce). Anoestrus and infertility may be reported in hypothyroid bitches, and prolonged oestrus has been reported in bitches with ovarian disorders and hyperoestrogenism (Davidson and Feldman, 1995).

Drug administration

The clinician should enquire about previous drug administration; for example, long-term glucocorticoid therapy may cause iatrogenic hyperglucocorticoidism. In addition, oestrogens and cytotoxic drugs, such as cyclophosphamide, may also interfere with hair growth. The response, or lack of response, to previous therapy may also be helpful; for example, failure of hair regrowth after 3–5 months of supplementation with T4 at an appropriate dose suggests that hypothyroidism is unlikely.

Clinical features

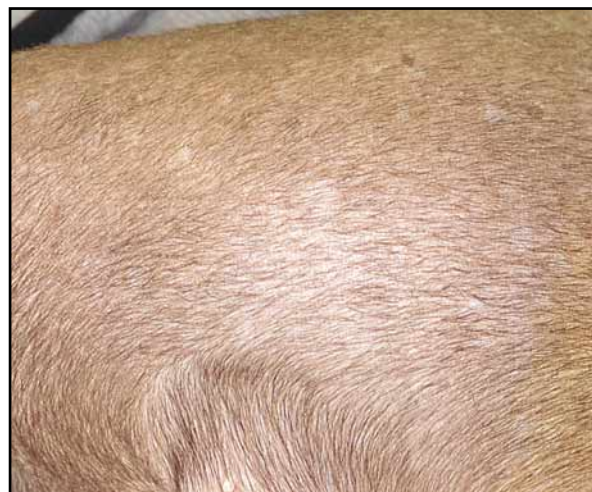A general physical examination can reveal clinical signs in other systems that may be related to the skin disease, particularly in dogs with hypothyroidism, hyperadrenocorticism and abnormalities of the reproductive system (see Figures 8.5 and 8.6). Although, it is important to appreciate that clinical signs may be confined to the skin in some dogs with these diseases, additional physical findings can be very helpful for listing differential diagnoses in order of priority, enabling further tests to be performed in a rational order. The reader is referred to other chapters in this text for comprehensive accounts of endocrine diseases of the dog.

Dermatological abnormalities

Physical examination of the skin should allow the clinician to determine whether the resultant alopecia is a scarring or non-scarring form.

- Scarring alopecias may show a predominance of lesions such as erythema, papules, pustules, furuncles and crusts.
- Alopecia without cutaneous inflammation suggests either an atrophic disease, a follicular dysplasia, or matrix cell/melanocyte abnormalities.

Coat colour change: Colour dilution alopecia (Figure 8.7) should be strongly suspected if the dog has a dilute coat colour (e.g. blue Dobermann Pinscher). Black hair follicular dysplasia should be considered if the alopecia is confined to black (or dark) haired areas; these two diseases usually develop during the first year of life (Carlotti, 1990; Miller, 1990a).



8.7

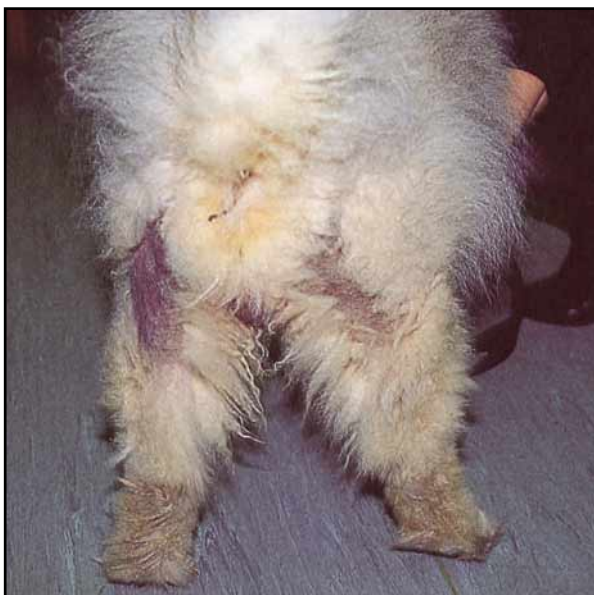Diffuse truncal hypotrichosis in a Dobermann Pinscher with colour dilution alopecia.

A lightening of the coat colour (leucotrichia) is not uncommon in dogs with hyperadrenocorticism. Changes in coat colour and coat quality are also seen in many of the follicular dysplasias (Gross *et al.*, 1992). The presence of miniaturized ('vellus') hairs is a key feature in *acquired pattern alopecia* (pattern baldness, see Figure 8.6), a rare disease usually seen in dachshunds that present with symmetrical non-inflammatory alopecia of the pinnae and/or the ventrum (Scott *et al.* 2001a).

Hyperpigmentation: Intense hyperpigmentation of the alopecic areas is most commonly seen in dogs with seasonal flank alopecia and 'alopecia X'. Alopecia X is a poorly defined disorder principally recognized in 'plush-coated' breeds such as the Pomeranian, Miniature Poodle, Chow Chow, Keeshond, Samoyed and Alaskan Malamute. This disorder has previously been termed:

- Adrenal sex hormone imbalance
- Growth hormone-responsive dermatosis
- Adult-onset hyposomatotropism
- Castration-responsive dermatosis
- Congenital adrenal hyperplasia
- Pseudo-Cushing's disease.

These names reflect the lack of clear understanding of the pathogenesis, although recent data suggest that this condition is associated with mild pituitary-dependent hyperadrenocorticism (Cerundolo *et al.*, 2001). Alopecia is often first observed between 1 and 5 years of age. Both male and female, neutered and entire, dogs are affected. Symmetrical alopecia affects the trunk, caudal thighs, perineum or neck, and changes in coat colour and coat quality may also be seen (Figure 8.8). Hair regrowth is often observed at sites of trauma, such as skin biopsy sites.



8.8 Bilaterally symmetrical alopecia with intense hyperpigmentation on the caudal aspect of the thighs in a 3-year-old Chow Chow with alopecia X.

Additional skin lesions: Dogs with symmetrical alopecia should be carefully evaluated for additional skin lesions. Comedones (blackheads), which are dilated hair follicles plugged with keratin and sebaceous debris, commonly develop in endocrine diseases. However, they may also be seen in demodicosis and in primary defects of keratinization affecting the upper portion of the hair follicle. Thinning of the skin with prominent subcutaneous vessels occurs in hyperadrenocorticism, whereas dogs with hypothyroidism may have thickened skin due to increased deposition of dermal mucin (myxoedema). In hyperadrenocorticism, the deposition of calcium salts along dermal collagen fibres may result in calcinosis cutis; lesions consist of yellow or white papules, nodules and plaques which feel firm and gritty when palpated.

Laboratory investigation

Laboratory tests are required for the definitive diagnosis of most cases of symmetrical alopecia.

Skin scrapings and plucked hairs

The microscopic examination of skin scrapings for demodicid mites is probably warranted in all cases of canine alopecia. In dogs with non-inflammatory symmetrical alopecia microscope examinations of plucked hairs (trichograms) and skin biopsy specimens may also be of value. Dysplastic diseases and melanocyte disorders are often characterized by the production of hairs with structural abnormalities, which can be detected by microscopy; for example, large melanin clumps with hair shaft distortion and fracture may be seen in colour dilution alopecia and black hair follicular dysplasia (Miller, 1990a; Hargis *et al.*, 1991). Alternatively, the presence of large numbers of easily epilated 'club' hairs suggests the arrest of the hair growth cycle in the telogen phase, as seen in endocrine diseases.

Skin biopsy

Skin biopsy is required for the diagnosis of follicular dysplasias and matrix cell/melanocyte abnormalities. Biopsies are also indicated in cases where the diagnosis cannot be readily confirmed by other means. As a general rule, multiple biopsy specimens should be obtained from the most alopecic areas (Gross *et al.*, 1992); samples from marginal areas may be confusing because growing hairs may still be present.

However, in alopecia areata, a rare disease associated with a lymphocytic cellular infiltrate centred around the hair matrix and dermal papilla, the key histopathological feature may be observed only in specimens obtained from the periphery of the lesion. Few of the atrophic diseases can be definitively diagnosed by histopathological examination of skin alone; other clinical or laboratory data are usually required.

However, certain histopathological features suggesting one particular form of endocrine disease over another may be present in occasional specimens, and the absence of particular changes may allow the endocrine impersonators to be excluded. The histopathological changes in hair follicle diseases can be subtle and it may be preferable to submit biopsy specimens to

a veterinary pathologist with a special interest in skin disease. The reader is referred to dermatopathology texts for a more detailed discussion of this area.

Screening laboratory tests

Urine and blood should be obtained from dogs suspected of having an endocrine disease for haematological and biochemical analyses as appropriate. The biochemical profile should include, at least, measurements of:

- Total protein
- Albumin
- Alkaline phosphatase
- Alanine aminotransferase
- Bilirubin
- Calcium
- Phosphate
- Urea
- Creatinine
- Cholesterol
- Glucose.

Urinalysis should include: a chemistry strip; sediment examination; measurement of specific gravity; and possibly bacterial culture. The laboratory findings may support a diagnosis of a particular endocrine disease, and specific hormone assays can then be performed as indicated (Figure 8.9).

Hormone assays

Specific assays for most of the relevant hormones are readily available. Often, dynamic tests of endocrine function are required because basal hormone concentrations may fluctuate widely in response to both physiological and pathological factors (Scott *et al.*, 2001b).

Thyroid and adrenal function: Tests designed to assess thyroid and adrenal function (see Chapters 10 and 15) are mandatory in dogs when clinical signs and

laboratory test results suggest hypothyroidism and/or hyperadrenocorticism. Thyroid and adrenal function should also be routinely assessed in dogs that have atrophic follicular diseases without other historical, clinical and laboratory features of endocrine diseases. This is because the more typical features of hypothyroidism and hyperadrenocorticism do not occur in all cases.

Oestrogens: Basal oestradiol concentrations are elevated in some dogs with hyperoestrogenism, but it has been noted that these can be normal even in affected dogs. It has been suggested in these cases that hyperoestrogenism results from the excessive production of other hormones such as oestrone and oestriol (Paradis, 2002).

17-Hydroxyprogesterone: The measurement of 17-hydroxyprogesterone before and after stimulation by adrenocorticotrophic hormone (ACTH) has been recommended in the investigation of dogs with alopecia X as an indicator of abnormal steroidogenesis (Schmeitzel *et al.*, 1995; Cerundolo *et al.*, 2001). Concentrations of 17-hydroxyprogesterone were elevated post-ACTH stimulation in all 31 affected Pomeranians studied by Cerundolo *et al.* (2001). Whilst an elevation of 17-hydroxyprogesterone supports, in part, a diagnosis of alopecia X, following exclusion of classical hyperadrenocorticism and hypothyroidism, the role of the hormone in the development of hair loss is unclear.

Treatment

Specific treatment is available for most of the endocrinopathies but is not possible in dogs with follicular dysplasias or matrix cell/melanocyte abnormalities. In general, the treatment of dogs with symmetrical alopecia by hormonal supplementation, without a specific indication based on laboratory testing, is to be discouraged.

Disease	Haemogram	Blood biochemical profile	Urinalysis	Hormone assays
Hypothyroidism	Normocytic, normochromic, non-regenerative anaemia	Hypercholesterolaemia, hypertriglyceridaemia	Normal	Low basal total or free T4 and high TSH concentrations. Lack of T4 stimulation in response to TSH or TRH administration
Hyperadrenocorticism	Stress leucogram	Elevated ALP, elevated ALT, elevated cholesterol	Specific gravity at <1.015, Urinary tract infection	Excessive cortisol response to ACTH administration. Elevated urine cortisol:creatinine ratio. Inadequate suppression of cortisol after administration of low-dose of dexamethasone
Hyperoestrogenism	Non-regenerative anaemia, thrombocytopenia, myeloid hyperplasia or hypoplasia	Normal	Normal	Elevated oestradiol or other oestrogens?
Alopecia X	Normal	Normal	Normal	High concentrations of 17-hydroxyprogesterone in response to ACTH administration

8.9 Results of laboratory tests in dogs with symmetrical alopecia caused by endocrinopathies. (Intended only as a guide. In some cases, the listed features may be absent). ACTH, adrenocorticotrophic hormone; ALP, alkaline phosphatase; ALT, alanine aminotransferase; T4, thyroxine; TRH, thyroid releasing hormone; TSH, thyroid stimulating hormone.

Hypothyroidism and hyperadrenocorticism

Treatment of hypothyroidism and hyperadrenocorticism is described in Chapters 10 and 15.

Alopecia X

Dogs with alopecia X may respond to: castration; trilostane; methyltestosterone; mitotane; or growth hormone (Schmeitzel *et al.*, 1995). Castration of the intact male dog may be the first treatment of choice.

Trilostane is an inhibitor of 3-beta-hydroxysteroid dehydrogenase and has recently been licensed in the UK for the treatment of canine hyperadrenocorticism (Neiger *et al.*, 2002). Cerundolo *et al.* (unpublished data) successfully treated 8 of 8 Miniature Poodles and 14 of 16 Pomeranians with alopecia X, using trilostane at 30 mg orally once daily for dogs <5 kg and 60 mg orally once daily for dogs >5 kg. Hair regrowth was usually noted within 4–8 weeks.

Mitotane is often effective in the treatment of this disorder. An initial dose of 15–25 mg/kg orally daily for 5 days is followed by maintenance doses of 15–25 mg/kg orally every 7–14 days (Schmeitzel and Parker, 1993; Schmeitzel *et al.*, 1995). Patients should be carefully monitored for signs of hypocortisolaemia, hyperkalaemia and hyponatraemia, particularly during initial therapy. Hair regrowth is often evident within 4–12 weeks.

In neutered male dogs, methyltestosterone supplementation at 1 mg/kg orally every other day (maximum dose 30 mg) for 3 months, followed by weekly maintenance therapy, may be attempted. However, behavioural changes, seborrhoea oleosa and hepatic disease are potential adverse effects (Schmeitzel *et al.*, 1995).

Although some dogs respond favourably to growth hormone supplementation, this hormone is immunogenic, potentially diabetogenic and difficult to obtain and therefore cannot be recommended.

Oestrogen- and testosterone-responsive dermatoses

A response to trial therapy is required to establish the diagnosis of both oestrogen-responsive and testosterone-responsive dermatoses; these diagnoses are rarely made in carefully evaluated cases. Supplementation with oestrogen or testosterone is potentially hazardous and they should only be used in cases where other more common endocrine diseases have been excluded definitively. Some owners prefer to accept the alopecia once the clinician has explained the potential adverse effects of supplementation with these hormones. Dogs with gonadal neoplasia without evidence of metastases should be neutered.

Seasonal flank alopecia

Therapy is not currently available for seasonal flank alopecia; however, in one study Paradis (1995) reported that the next predicted episode of alopecia was prevented by melatonin supplementation in all nine dogs treated. There is no rationale for supplementation with thyroid, reproductive and growth hormones in seasonal flank alopecia (Curtis *et al.*, 1996).

Follicular dysplasias and matrix cell/melanocyte abnormalities

Only palliative therapy is available for dogs with follicular dysplasias and matrix cell/melanocyte abnormalities. Any secondary pyoderma should be treated with an antibacterial agent effective against *Staphylococcus intermedius*, such as lincomycin or cefalexin. Topical therapy with shampoos may be helpful in dogs with scaling disorders, and as adjunctive therapy in superficial pyoderma.

References and further reading

- Carlotti DN (1990) Canine hereditary black hair follicular dysplasia and colour mutant alopecia: clinical and histopathological aspects. In: *Advances in Veterinary Dermatology*. Vol 1, ed. C von Tschanner and REW Halliwell, pp. 43–46. Baillière Tindall, London
- Cerundolo R, Lloyd DH, Evans H, Mol JA, Vaessen MMAR, Kooistra HS and Rijnberk A (2001) Alopecia in Pomeranians and miniature poodles is associated with mild pituitary-dependent hyperadrenocorticism. *Proceedings of the International Symposium 'Comparative Clinical and Molecular Endocrinology', Utrecht* (The Netherlands), August 2001, pp. 29–31
- Curtis CF (1995) Clinical features of canine idiopathic cyclical flank alopecia. *Veterinary Dermatology Newsletter* **17**, 53–54
- Curtis CF, Evans H and Lloyd DH (1996) Investigation of the reproductive and growth hormone status of dogs affected by idiopathic recurrent flank alopecia. *Journal of Small Animal Practice* **37**, 417–422
- Davidson AP and Feldman EC (1995) Ovarian and oestrus cycle abnormalities in the bitch. In: *Textbook of Veterinary Internal Medicine, 4th edn*, ed. SJ Ettinger and EC Feldman, pp. 1607–1613. WB Saunders, Philadelphia
- Dunstan RW (1995) A pathomechanistic approach to diseases of the hair follicle. *Veterinary Dermatology Newsletter* **17**, 37–41
- Ebling FJG, Hale PA and Randall VA (1991) Hormones and hair growth. In: *Physiology, Biochemistry, and Molecular Biology of the Skin*, ed. LA Goldsmith, pp. 660–696. Oxford University Press, New York
- Foster AP and Foil CS (2003) *BSAVA Manual of Small Animal Dermatology, 2nd edn*. BSAVA, Gloucester
- Gross TL, Ihrke PJ and Walder EJ (1992) *Veterinary Dermatopathology: a macroscopic and microscopic evaluation of canine and feline skin disease*, pp. 273–309 Mosby Year Book, St. Louis
- Hargis AM, Brignac MM, Kareem Al-Bagdadi FA, Muggli F and Mundell A (1991) Black hair follicular dysplasia in black and white Saluki dogs: differentiation from colour mutant alopecia in the Doberman Pinscher by microscopic examination of hairs. *Veterinary Dermatology* **2**, 69–83
- Hoskins JD (2001) The skin and claws. In: *Veterinary Pediatrics*, ed. JM Hoskins, pp. 225–261. WB Saunders, Philadelphia
- Ihrke PJ, Mueller RS and Stannard AA (1993) Generalized congenital hypotrichosis in a female Rottweiler. *Veterinary Dermatology* **4**, 65–69
- Jahoda CAB and Oliver RF (1990) The dermal papilla and the growth of hair. In: *Hair and Hair Diseases*, ed. CE Orfanos and R Happle, pp. 19–44. Springer-Verlag, Berlin
- Kristensen S (1975) A study of skin disease in dogs and cats. I. Histology of the hairy skin of dogs and cats. *Nordisk Veterinaermedicin* **27**, 593–603
- Miller WH (1990a) Colour dilution alopecia in Doberman Pinschers with blue or fawn coat colours: a study on the incidence and histopathology of this disorder. *Veterinary Dermatology* **1**, 113–122
- Miller WH (1990b) Follicular dysplasia in adult black and red Doberman Pinschers. *Veterinary Dermatology* **1**, 181–187
- Miller MA and Dunstan RW (1993) Seasonal flank alopecia in Boxers and Airedale terriers: 24 cases (1985–1992). *Journal of the American Veterinary Medical Association* **203**, 1567–1572
- Miller WH and Scott DW (1995) Follicular dysplasia of the Portuguese Water dog. *Veterinary Dermatology* **6**, 67–74
- Neiger R, Ramsey I, O'Connor J, Hurley KJ and Mooney CT (2002) Trilostane treatment of 78 dogs with pituitary-dependent hyperadrenocorticism. *Veterinary Record* **150**, 799–804
- Paradis, M (1995) Canine recurrent flank alopecia: treatment with melatonin. *Proceedings of the American College of Veterinary Dermatology Annual Meeting, Santa Fe, 1995*, p. 49
- Paradis, M (2002) Gonadal sex hormone alopecias. *British Veterinary Dermatology Study Group Proceedings, Autumn Meeting, Harlow*, pp. 39–46

Chapter 8 Investigation of symmetrical alopecia in dogs

- Paradis M and Cerundolo R (2003) An approach to symmetrical alopecia in the dog. In: *BSAVA Manual of Small Animal Dermatology, 2nd edn*, ed. AP Foster and CS Foil, pp. 83–93. BSAVA, Gloucester
- Schmeitzel LP, Lothrop CD and Rosenkrantz WS (1995) Congenital adrenal hyperplasia-like syndrome. In: *Kirk's Current Veterinary Therapy XII*, ed. JD Bonagura, pp. 600–604. WB Saunders, Philadelphia
- Schmeitzel LP and Parker W (1993) Growth hormone and sex hormone alopecia. In: *Advances in Veterinary Dermatology, Volume 2*, ed. PJ Ihrke, IS Mason and SD White, pp. 451–454. Pergamon Press, Oxford
- Scott DW, Miller WH and Griffin CE (2001a) Acquired alopecia. *Muller and Kirk's Small Animal Dermatology*, pp. 887–912. WB Saunders, Philadelphia
- Scott DW, Miller WH and Griffin CE (2001b) Endocrine and metabolic disease. *Muller and Kirk's Small Animal Dermatology*, pp. 780–885. WB Saunders, Philadelphia
- Yager JA and Wilcock BP (1994) Atrophic dermatoses. In: *Colour Atlas and Text of Surgical Pathology in the Dog and Cat. Dermatopathology and Skin Tumors*, pp. 217–237. Wolfe Publishing, London
-